

CASE STUDY

Neocortical: Primary Motor

34 year old right handed man presents with 10 to 20 simple partial motor seizures a month beginning with left hand clonic movements spreading to left arm and face.

HISTORY

Seizure onset: 30 years of age

Prior treatments: failed trials of 3 antiepileptic medications

MRI: right frontal cryptic arteriovenous malformation (AVM) with margin of hemosiderin

Intracranial EEG: ictal onset corresponds to lesion; functional mapping indicates that ictal onset overlaps with primary motor cortex

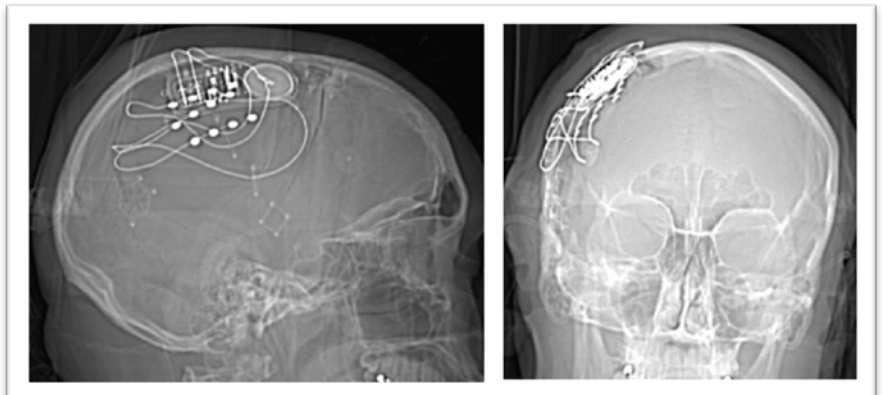
Resection of AVM with posterior margin of resection anterior to left hand area. Seizure frequency not changed.

EVALUATION & PLAN

- Partial onset seizures arising from right primary motor cortex, hand area
- Lesionectomy did not achieve seizure control; at risk for weakness in left hand with additional resection
- Candidate for treatment with the RNS System with responsive stimulation to primary motor cortex

LEAD IMPLANT STRATEGY

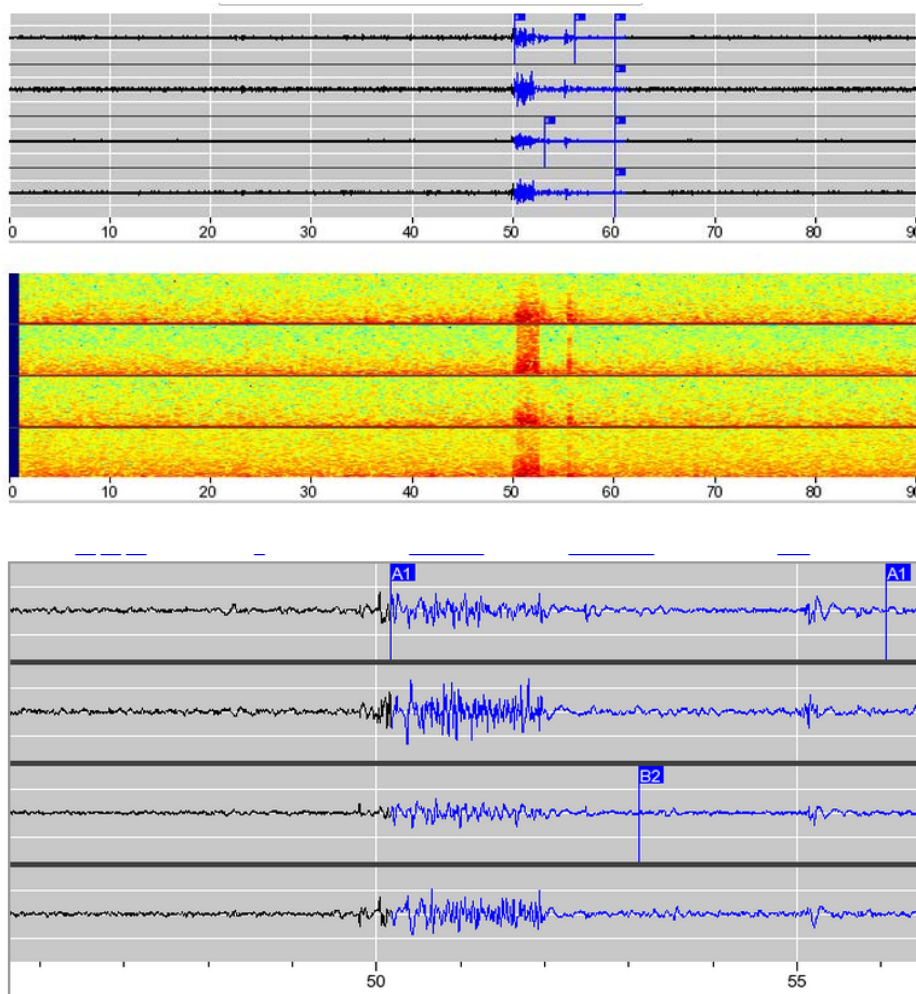
3 frontoparietal strips*; middle and inferior strips connected to neurostimulator





ECOG

ECoG recordings before neurostimulator has been programmed to provide responsive stimulation. Epileptiform discharges are detected in electrodes from the middle (A1) and inferior (B2) strips. The ECoG and corresponding Fast Fourier Transform (FFT) are shown above an expanded view of the ECoG.



*Only 2 leads are connected to the neurostimulator at once.

This case study is a composite adapted from actual case files; results are not necessarily representative of the patient population.

R_XOnly

See important prescribing and safety information in the RNS[®] System labeling. This is intended as supplementary information and should be used in conjunction with the labeling. Refer to the labeling for a description of the RNS[®] System and its components, indications for use, contraindications, warnings, cautions, adverse events and instructions for use. The manuals are available at www.NeuroPace.com.

©2015 NeuroPace, Inc. All rights reserved. NeuroPace[®] and RNS[®] are registered trademarks of NeuroPace, Inc. NeuroPace, Inc | 455 N. Bernardo Ave., Mountain View, CA 94043. NP 150094 Rev 1/Rev. Date: 2015-10.