

## CASE STUDY

# Neocortical: Parietal

36 year old woman with 5 to 10 seizures a month that awaken her from sleep with left arm and abdominal pain lasting 15 seconds, after which she loses awareness. Her husband reports that she has heavy labored breathing and staring and is often incontinent of urine. Generalized tonic clonic seizures occur about twice a month.

## HISTORY

---

**Seizure onset:** 32 years of age coincident with a pregnancy

**Prior treatments:** Failed trials of 2 antiepileptic medications

**MRI:** evidence for small cortical lesions in the post-central gyrus and lateral temporal lobe consistent with right mesial cerebral artery emboli

**Scalp EEG:** wide spread rhythmic theta over C4, P4, T4 and T6 with seizure

**Intracranial EEG and mapping:** grid over right frontal and parietal lobe indicates ictal onset corresponds to left arm primary sensory cortex

## EVALUATION & PLAN

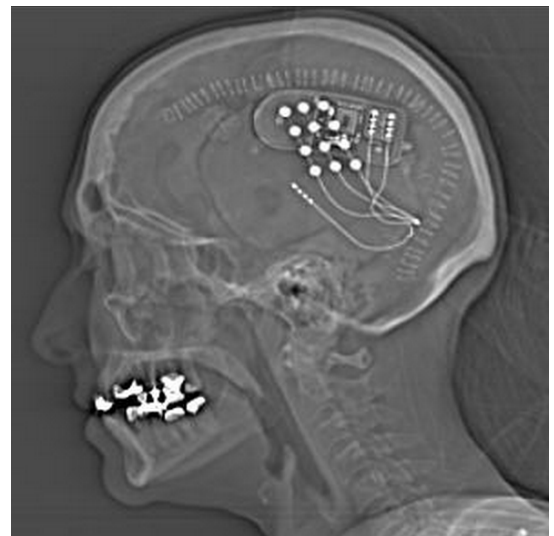
---

- Partial onset seizures of right primary sensory cortex
- At risk for left arm sensory deficits with resection of seizure focus
- Candidate for RNS System with responsive stimulation to post-central gyrus corresponding to left arm sensory cortex

## LEAD IMPLANT STRATEGY

---

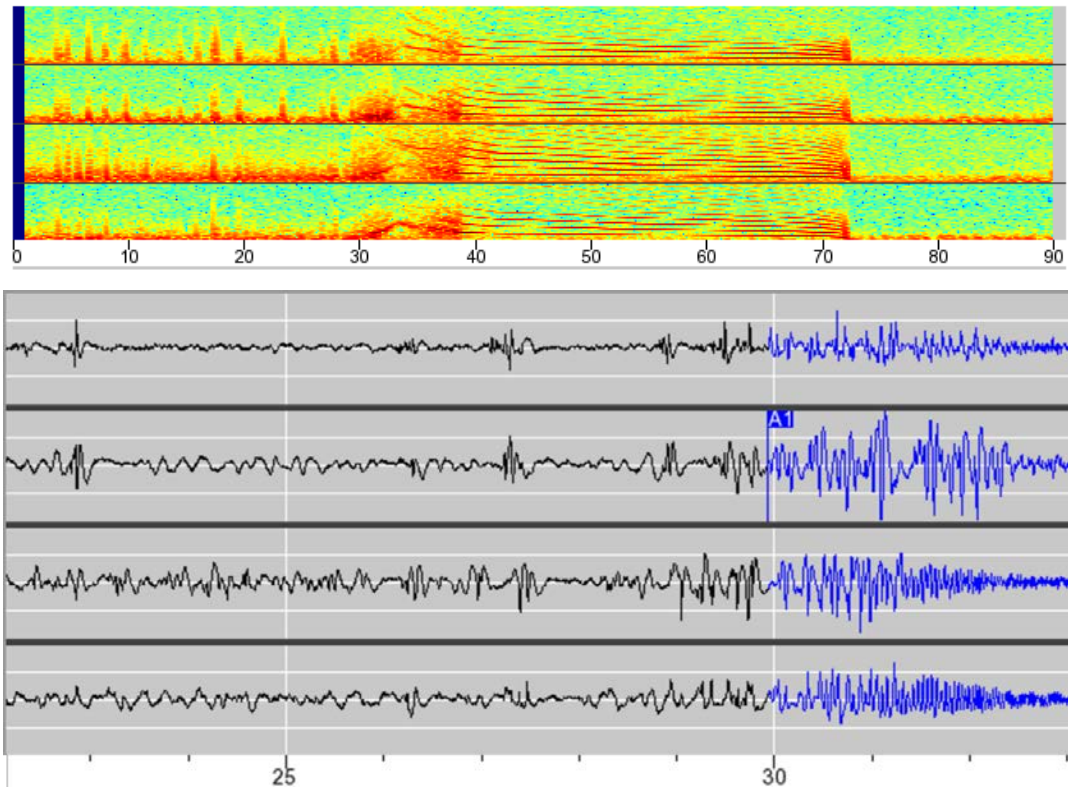
3 parietal strip leads\*





## ECOG

Electrographic seizure obtained from depth leads placed anterior (top 2 channels) and posterior (bottom 2 channels) to cortical dysplasia. The detection occurs at A1. The top image is a spectral array display (Fourier transform) and the bottom image is an ECoG display. Time is indicated on the X axis.



\*Only 2 leads are connected to the neurostimulator at once.

This case study is a composite adapted from actual case files; results are not necessarily representative of the patient population.

**R<sub>X</sub>Only**

See important prescribing and safety information in the RNS® System labeling. This is intended as supplementary information and should be used in conjunction with the labeling. Refer to the labeling for a description of the RNS® System and its components, indications for use, contraindications, warnings, cautions, adverse events and instructions for use. The manuals are available at [www.NeuroPace.com](http://www.NeuroPace.com).

©2015 NeuroPace, Inc. All rights reserved. NeuroPace® and RNS® are registered trademarks of NeuroPace, Inc. NeuroPace, Inc | 455 N. Bernardo Ave., Mountain View, CA 94043. NP 150097 Rev 1/Rev. Date: 2015-10.