

## CASE STUDY

# Mesial Temporal: Unilateral

32 year old woman presents with 3 to 4 seizures a month characterized by a rising epigastric sensation followed by loss of awareness and manual automatisms.

## HISTORY

---

**Seizure onset:** 15 years of age

**Seizure risk factors:** none

**Prior treatments:** failed trials of 4 antiepileptic medications

**Scalp EEG:** remarkable for interictal right temporal spikes (F8/T4); video-EEG captured 3 typical seizures with right anterior temporal ictal onset

**MRI:** normal

**Intracarotid Amytal (Wada) test:** left hemisphere language dominant, normal recall after left injection

**Neuropsychological testing:** normal visual and verbal memory

## EVALUATION & PLAN

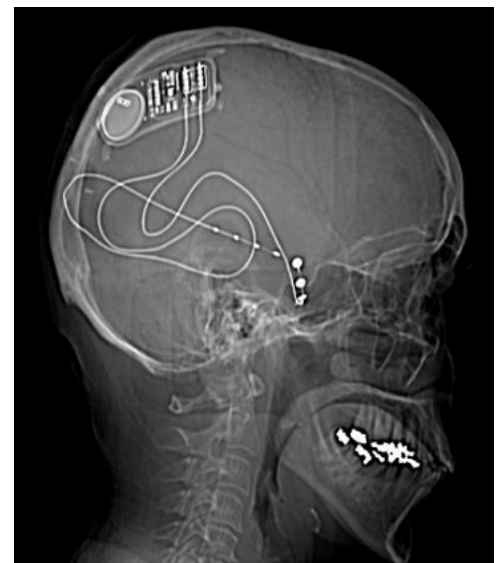---

- Partial onset seizures of left mesial temporal lobe origin
- At risk for memory and language deficits following left temporal lobe resective surgery
- Candidate for RNS System with left mesial temporal responsive stimulation

## LEAD IMPLANT STRATEGY

---

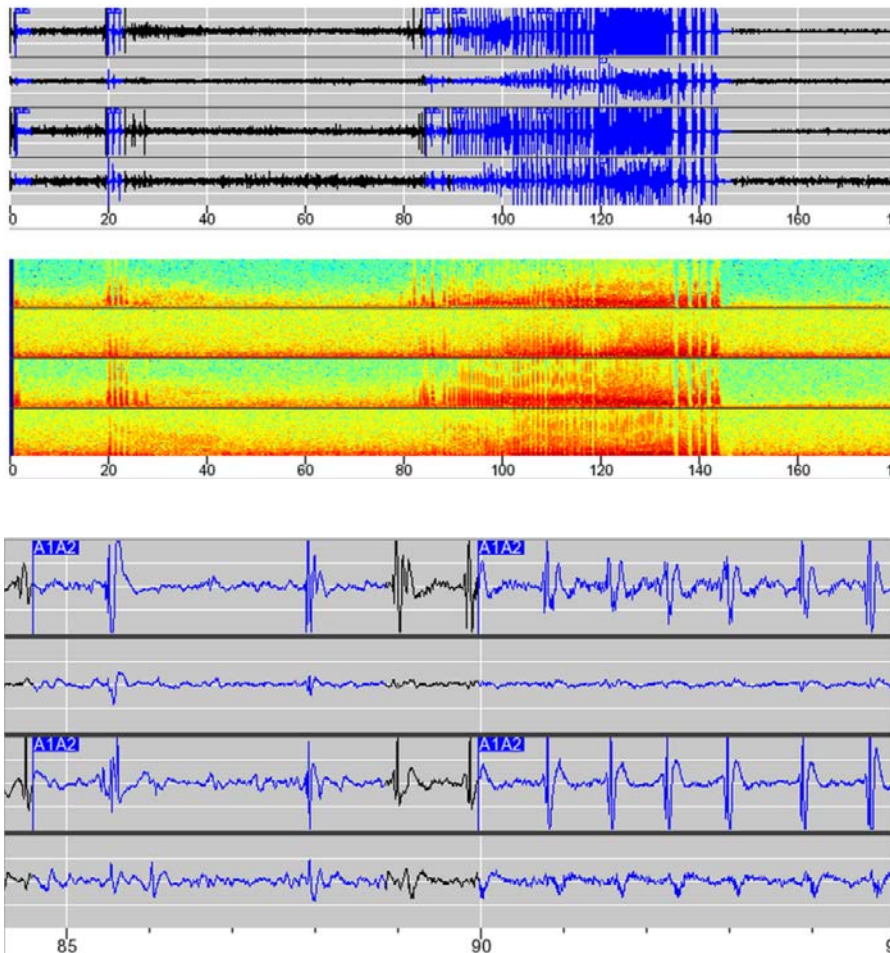
- 1 hippocampal depth lead: occipital approach along long axis of hippocampus
- 1 subtemporal cortical strip lead





**ECOG**

Electrographic seizure detected before neurostimulator has been programmed to provide responsive stimulation. The top 2 channels are recording from the hippocampal depth lead and the bottom 2 channels from the subtemporal strip lead. A1A2 marker indicates the simultaneous detection of hypersynchronous activity on the depth and strip leads. The ECoG and corresponding Fast Fourier Transform (FFT) are shown above an expanded view of the ECoG. Time is indicated on the X axis.



This case study is a composite adapted from actual case files; results are not necessarily representative of the patient population.

**R<sub>X</sub>Only** See important prescribing and safety information in the RNS® System labeling. This is intended as supplementary information and should be used in conjunction with the labeling. Refer to the labeling for a description of the RNS® System and its components, indications for use, contraindications, warnings, cautions, adverse events and instructions for use. The manuals are available at [www.NeuroPace.com](http://www.NeuroPace.com).

©2015 NeuroPace, Inc. All rights reserved. NeuroPace® and RNS® are registered trademarks of NeuroPace, Inc. NeuroPace, Inc | 455 N. Bernardo Ave., Mountain View, CA 94043. NP 150090 Rev 1/Rev. Date: 2015-10.